

Immediate loading with single phase implants

Recent clinical studies have concentrated increasingly on the search for new treatment strategies, resulting in a reduction in the time taken for treatment with dental implants.

As a consequence single-phase implants and their forms of prosthetic treatment are gaining increasing interest and popularity amongst experts.

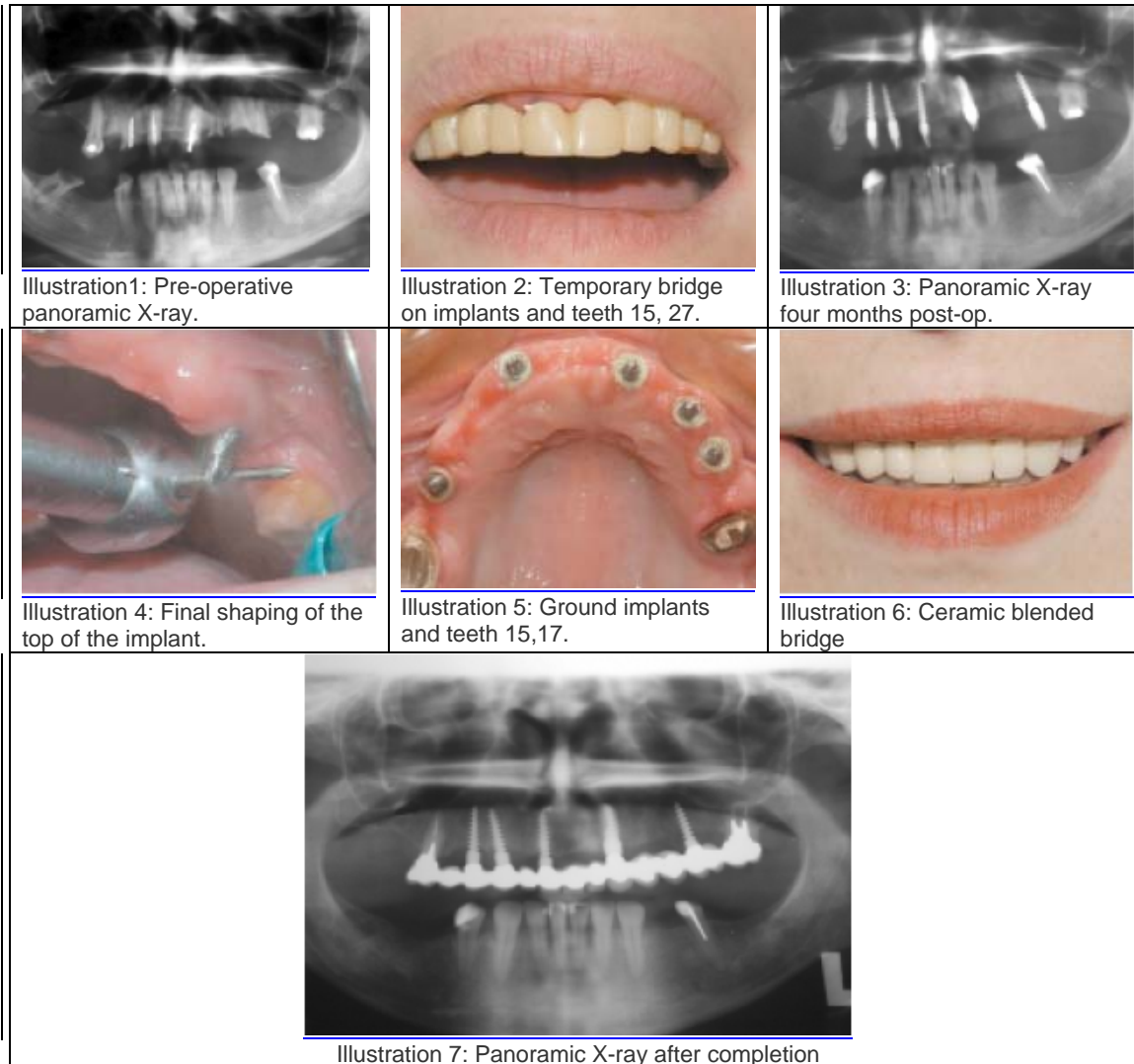
Dr. Med. Dent. MARIUSZ DUDA/KATOWICE

In the case of Q Implants (TRINON) the sensible combination of surgical planning and use of prosthesis means that complex treatment is no longer necessary and as a result treatment is more useful and patient-orientated. Less time is lost for patients from implantation to the full integration of the prosthesis. Thus there have been highly promising clinical results in the course of the single-phase treatment, combined with immediate prosthesis loading straight after implantation.

Clinical description of a patient case

A 37-year-old female patient wanted prosthetic restructuring and due to the nature of her job, cosmetic results were of the greatest importance. After thorough planning, the 16,14,13,12,21,22,23 and 24 teeth were earmarked for surgical removal (Illustration 1). A complete curettage of the alveola and smoothing of the alveolar ridges followed. To insert the Q Implant, the supporting bones between the alveola 14-13, 13-12 and 22-23 were used for structural and prosthetic reasons – positions 15 and 25 were given conventional implants. A high level of primary stability was attained in all the Q Implants inserted, due to the special design of the screw thread (calibre used: Q Implant 3Q 14 mm, 4Q 14 mm – TRINON Titanium).

After closing with sutures and using a dental dam, the top of the implants were extensively ground. A temporary bridge was then made for teeth 15-27, which was then temporarily cemented and worn for four months (Illustration 2). Post-operative healing proceeded without complications. After this time (Illustration 3) the implants were ground



once again – the aim now being to prepare a high-quality, cosmetic hollow space (Illustration 4). The overall treatment was completed, much to the satisfaction of the dentist and the patient, with a metal ceramic bridge with ceramic stages and an anatomically moulded pontic bed (Illustrations 5 to 7).

Summary

Based on extensive clinical and histological studies in the last decade, the immediate loading of implants has proved to be an important part in dental implantology. It has been proved that immediate loading of implants does not have a negative impact on the formation and mineralization of the peri-implant tissue during osteointegration. In addition, recent research has shown that the immediate loading of single-phase implants, when compared to the classic two-phase implant procedure, achieves the same results for prosthetic bridges, pontics or crowns.

With the discontinuation of the operation to open up the area (secondary surgical operation) and the simplification of the laboratory process, treatment time is effectively shortened with Q implants, as is the related wound-healing phase. It is not surprising that immediate loading seems to increase the level of ossification of the peri-implant bone tissue. Biomechanically retained implants (e.g. en bloc combined implants as a bridge in the lower jaw) have a positive influence on the remodelling process of osteointegration and stimulate bones to reorganise. Scientific tests on Q implant systems have shown that their primary stability makes immediate loading possible and that the immediately inserted prostheses are more secure.

To summarise, to the user Q implants present numerous treatment possibilities for surgical planning and prosthetic implementation, while using modern implantology concepts.

Literature:

- 1 Aires, I; Berger, J: Immediate placement in extraction sites followed by immediate loading: a pilot study and case presentation. *Implant-Dent.* 2002; 11(1): 87–94.
- 2 Degidi, M; Petrone, G; Iezzi, G; Piattelli, A: Histologic evaluation of a human immediately loaded titanium implant with a porous anodized surface. *Clin-Implant-Dent-Relat-Res.* 2002; 4(2):110–114.
- 3 Duda M, Kurrek A, Krezlik E, Krezlik A: Einphasenimplantat bei Sinuslifting-Eingriffen. *ZWP Zahnarzt Wirtschaft Praxis*, 2003, 9:32–34.
- 4 Exbrayat, P: Early intraoral splinting and loading of one-stage dental implants in the edentulous mandible: literature review and case report. *Pract-Proced-Aesthet-Dent.* 2002 Sep; 14(7):529–36; quiz 538.
- 5 Hruska, AR; Borelli, P: Intra-oral welding of implants for an immediate load with overdentures. *J-Oral-Implantol.* 1993; 19(1):34–38.
- 6 Romanos, GE; Toh, CG; Siar, CH; Swaminathan, D: Histologic and histomorphometric evaluation of peri-implant bone subjected to immediate loading: an experimental study with *Macaca fascicularis*. *Int-J-Oral-Maxillofac-Implants.* 2002 Jan–Feb; 17(1):44–51.
- 7 Siddiqui, AA; Ismail, JY; Kukunas, S: Immediate loading of dental implants in the edentulous mandible: a preliminary case report from an international prospective multicenter study. *Compend-Contin-Educ-Dent.* 2001 Oct; 22(10):867–70, 873–4, 876 passim; quiz 8

Correspondance address: :

*Dr. med. dent. Mariusz Duda
Silesia – Med, Oral Surgery Clinic
Mielęckiego 6, 40-013, Katowice, Polen
Tel.: 00 48/5 04/82 97 51, Fax: 00 48/32/2 53 86 84
www.silesia-med.com.pl*

Abb. 7: Panoramaröntgenaufnahme nach Fertigstellung.

Con formato: Alemán (Alemania)

Con formato: Alemán (Alemania)

Con formato: Alemán (Alemania)

Con formato: Alemán (Alemania)

Con formato: Alemán (Alemania)

Con formato: Alemán (Alemania)

Con formato: Alemán (Alemania)

Con formato: Alemán (Alemania)

Eliminado: 84.

